

# Direct anterior hip approach versus modified Hardinge approach for total hip arthroplasty in adults

Ayman Fathy, MD and Saleh gamee, MD;

Lecturer of Orthopedic surgery Ain Shams University

## **Corresponding author:**

Ayman Fathy; Lecturer of Orthopedic surgery, Ain Shams University Hospitals

## **Address of the correspondence:**

[dr.ayman.ortho@gmail.com](mailto:dr.ayman.ortho@gmail.com)

2 Saad abdelwares st, New Nozha, Cairo, Egypt.

Phone number:00201001309880

ORCID: 0000-0002-0832-2296

**The Egyptian Orthopedic Journal; 2019 supplement (2), December, 54: 49-53**

## **Abstract**

### **Introduction**

Total hip arthroplasty is a successful surgical treatment for painful hip conditions. Many studies compared operation time, rehabilitation time and complications in the different hip approaches. The direct anterior approach is one of the most recently studied approaches with excellent outcomes.

There is a strong tendency for surgical techniques to be improved over time and as new instruments are developed less invasive approaches are possible.

### **Patients and methods**

This study describes the initial experience of two senior orthopedic surgeons. The aim of the study was to describe early complications so that surgeons who utilise the technique will know potential benefits and the potential risks related to the technique.

In our study we compared hip scoring, rehabilitation time, surgical time and dislocation rates between traditional hip approaches and the direct anterior hip approach. Forty patients underwent primary total hip arthroplasty divided into two groups; one group done through the anterior approach and the other through the modified Hardinge approach.

### **Results**

The results show the direct anterior approach using a fracture table is an excellent technique which provides shorter postoperative rehabilitation due to less soft tissue trauma period and reduces the risk of dislocation.

### **Conclusion**

The benefits of the new technique should be balanced with a new group of complications and intraoperative difficulties and when the technique is more widely used more problems can become apparent.

### **Keywords**

Anterior hip approach; modified Hardinge approach; total hip arthroplasty; Instability.

## **Introduction**

Dislocation is the main early complication of total hip arthroplasty with the surgical approach and implant positioning are the main factors influencing total hip arthroplasty stability.[1]

Although great successes have been reported over many years, there is a constant push to modify the technique to allow improvement in patient outcome [2], complication rate, and increase efficiency in surgical technique.[3]

Currently the commonly used surgical exposures for hip replacement are the anterolateral and the posterolateral approaches; both involve splitting muscles with risk of partial denervation and detachment of tendons with a risk for incomplete healing. In many cases, this results in weakness of hip abductor muscles and notable limp [4,5].

The anterior approach to the hip for total hip arthro-

plasty has in the last ten years become more commonly used by surgeons for many reasons one of which is utilization anterior internervous and intermuscular plane.[4]

Due to the intermuscular nature, this approach allows faster patient recovery to ambulation, normal abductor strength, and decreased dislocation rate.[5,6] It also provides a better view of the acetabulum with visualization of the anterior iliac spine landmarks for appropriate cup positioning. However, the femur canal preparation and component placement is considered difficult with this approach.[7]

In our study, we reviewed the technique as performed at our hospital, outcome data in the context of recent literature using the anterior approach with a fracture table for total hip arthroplasty and comparing results using the modified lateral approach.

The learning curve for this technique is increasing

gradually as the surgeon gains experience with the surgical approach. Three main challenges the surgeon faces; first becoming familiar with the proximal femoral anatomy to decide the location of the femoral neck cut based on anatomic landmarks, second learning to adequately release the hip capsule from the proximal femur, and third learning to adequately lateralize the proximal femur when preparing the stem to avoid varus stem positioning and calcar fracture.[8-10]

## Patients and methods

A prospective study, including 40 patients with hip osteoarthritis who were candidates for total hip arthroplasty, was conducted in the period between January 2014 and January 2016. Twenty patients (Group A) were done using the anterior hip approach and the other twenty patients (Group B) were done using modified Hardinge approach. All were primary, unilateral hip replacements. Exclusion criteria were cases of severe deformity such as high hip dislocation or morbid obesity. All operations were done using a standard operating fracture table and the patient supine.

Regarding Group A, The hip was positioned at the table break in order to allow extension during the procedure. Both lower limbs were prepped and draped. A

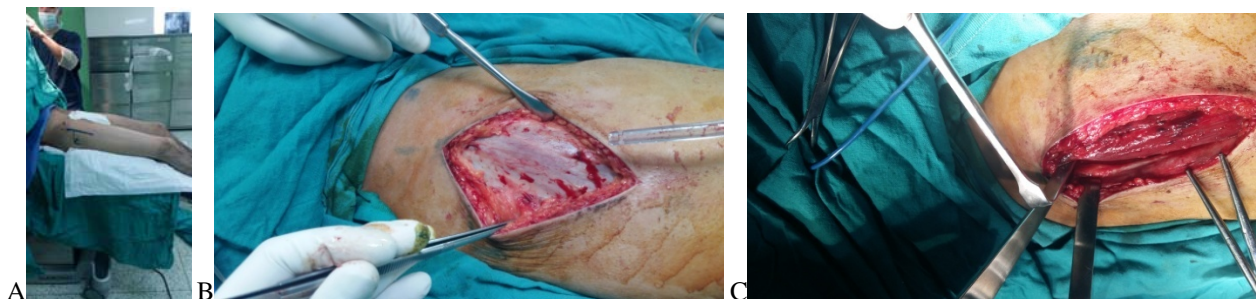
straight incision was placed two finger breadths anterior to the greater trochanter and extended proximally to the level of the anterior superior iliac spine.

The subcutaneous tissue and the fascia over the tensor fascia lata was split and the medial margin of the tensor muscle was approached subfascially then Hohmann retractors were placed deep to the muscle, one on the hip capsule and one on the vastus lateralis ridge of the greater trochanter. The joint was opened longitudinally, a part of the femoral neck was removed and the femoral head extracted using a cork-screw. Acetabular exposure was obtained using the special pointed retractors anteriorly and posterolaterally.

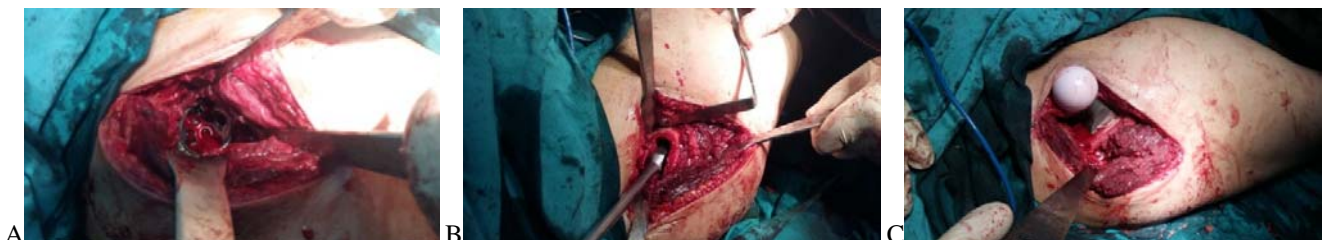After reaming, a hemispherical Zimmer Biomet acetabular cup was fixed aiming at 10–20° of anteversion and 40–50° of inclination. In order to get access to the proximal femur, the hip capsule was released posterolaterally so that the femur could be lifted using a special retractor behind the tip of the trochanter.

Broaching was facilitated by putting the leg into extension, adduction and external rotation. This step needs an experienced assistant on the same side.

We used cementless femoral component of Zimmer Biomet and a 28 mm head. The wound was then closed using resorbable sutures.



**Fig.(1):**Showing: (a) surgical incision landmarks of the anterior approach, (b) superficial dissection, (c) and deep dissection.



**Fig(2):** showing (a) acetabular preparation, (b) femoral preparation and (c) prereduction femoral and acetabular components application.

Regarding Group B, patients were positioned in the dead lateral decubitus position. We suspended the gluteus medius and gluteus minimus on stay sutures

and re-sutured them again at the end of operation. This preserves the gluteus minimus and avoids injury of branches of the superior gluteal nerve.

Twenty two patients were male and eighteen were female with age ranging from 49 to 79 years old.

The perioperative risks were discussed with the patients and their relatives. The postoperative expectations for function and mobility were discussed.

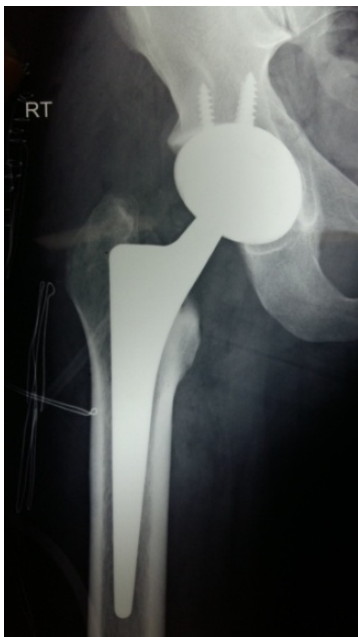Informed consent (approved by the Research Ethics Committee in Ain Shams University, Faculty of Medicine) was obtained from all individual participants included in the study. The preoperative radiological assessment was done by plain

radiography for planning and templating.

According to the patients' general condition, postoperative intensive care unit admission was done. Parenteral anticoagulation (enoxaparin—low molecular weight heparin) started 12 h postoperatively then dose adjustment and then shifting to oral anticoagulant was done.

Partial weight bearing was allowed as soon as the general condition of the patient permits under physiotherapist supervision. The figure of four positions, cross leg adduction, extreme lower limb rotations, and hip flexion of more than 100° positions were avoided.

Immediate postoperative X-ray was done for all patients to assess component alignment and stability and was repeated with every follow-up. Follow-up was done 3 weeks postoperatively for the removal of stitches, then regularly at 6 weeks, 12 weeks then every 6 months for the first 2 years postoperatively. Our results were evaluated according to the Hospital for special surgery—hip rating system.[11]



**Fig 3:** Postoperative x-ray of primary total hip arthroplasty done with anterior approach.

## Results

The mean age group of the patients was 62 years old for group A and 65 years old for group B. Three cases (two from Group A and one from Group B) had prolonged wound serous discharge for more than 4 days without fever. This prolonged discharge was diagnosed due to hypoalbuminemia. This patient received fresh frozen plasma and albumin, culture and sensitivity was done with no pus was found. The patient improved after elevation of the albumin level. The mean hospitalization period was 6.1 days. The mean follow-up period was 14.6 months. One case died due to heart failure.

Intraoperative complications included only one trochanteric fracture in Group(A), with no femoral perforations or fractures. There was no acetabular fractures or bleeding complications. The mean intraoperative blood loss was less in Group(A). Mean blood loss in Group(A) was .....while was .... in Group (B) .

Functionally, all our patients could do assisted walking postoperatively. According to the Hospital for special surgery—hip rating system functional evaluation—the grading system >31 is excellent, 24–31 is good, 16 to 23 is fair, and <16 is poor. After the end of follow-up, the final results were as follows: 12 patients were excellent, 19 patients were good, 5 patients were fair, and 3 patients were of poor rate. There was great difference between preoperative and postoperative results, with better relative overall postoperative results in Group(A) compared to Group(B).

The patients' function and quality of life were much better compared to their abilities before the primary hip injury except two of the patients due to overall worse medical condition. The postoperative limping was noted to be less in Group(A).

The mean operative time was more in Group(A) compared to Group(B), but it was decreasing gradually with increasing the learning curve throughout the study.

Regarding post-operative rehabilitation time, it was strikingly shorter, easier with less pain in Group(A) compared to Group(B), which was expected due to less soft tissue damage and due to the intermuscular , internervous plane during dissection.

Regarding postoperative complications, No hip dislocations or subluxation happened during the follow up period . Immediate postoperative X-rays showed cup inclination ranging from 42 to 52° with a mean of 45.1°. No radiologic or clinical signs of loosening or component migration were seen during the whole period of the follow-up X-rays.

**Table 1:** Comparison between patients of the lateral versus the anterior approach

	<b>GROUP(A)</b>	<b>GROUP(B)</b>
<b>Mean Age</b>	62yrs	65yrs
<b>Sex</b>	10 MALES, 15 FEMALES	12 MALES, 13 FEMALES
<b>Complications</b>	Two wound problems	One wound problem
<b>Postoperative Scoring</b>	Excellent:7 Good:10 Fair:2 Poor:1	Excellent:5 Good:9 Fair:3 Poor:2
<b>Intraoperative complications</b>	One Trochanteric fracture	None

## Discussion

Total hip arthroplasty is a successful surgical treatment for painful hip conditions with high return of function for patients post operatively.[12]

The four main surgical approaches to the hip for total hip arthroplasty utilize different intervals to the hip joint, each differs in relation to the risks and benefits according to the anatomic structures involved.[13]. For example post-operative dislocation rate, post-operative limp, nerve injury and patient function improvement, infection rates, heterotopic ossification, are factors which have been used to evaluate and compare total hip approaches.[14]

Access to the femoral canal while utilizing the anterior approach can be expected to be difficult especially in patients with a short and varus angulated femoral neck and where the range of motion is restricted due to fibrosis of the joint capsule. Other authors have reported fractures in the proximal femur with this approach.

In our study, the major predisposing factor seems to have been pronounced osteoporosis. With the currently used offset handle, broaching is safer than with a standard straight handle as in the present series. The risk for fracture of the proximal femur is also avoided by adequate posterolateral capsule release so that a hohmann can be placed around the tip of the trochanter while the hip is extended, adducted and externally rotated. Taking care not to release too much soft tissue to avoid risk of instability.

The technique is more technically demanding than the lateral approaches used today due to the somewhat less surgical exposure. Morbidly obese or very muscular patients as well as patients with a short femoral neck or acetabular protrusion can represent particular problems.

## Conclusion

With increasing number of patients demanding total hip arthroplasties and increasing hip prostheses designs, utilizing new different hip approaches and techniques has become mandatory to suit every patient case and indication.

The anterior hip approach has become more commonly used during the last decade in selected patients due to its advantages such as early recovery with less risk of instability .

In our opinion, the anterior hip approach should not be used as a routine for total hip arthroplasty but it is necessary to have a detailed understanding of the risks beforehand.

This technique should be reserved for specially trained surgeons who have the possibility to treat many patients in order to maintain good skills and different alternatives when approaching each case. It has been our overall impression that morbidly obese or very muscular patients as well as patients with a short femoral neck or acetabular protrusion can represent particular problems.

## Conflict of interest:

On behalf of all authors, the corresponding author states that there is no conflict of interest.

## References

1. Matta JM, Shahrardar C, Ferguson T. (2005) Single-incision anterior approach for total hip arthroplasty on an orthopaedic table. *Clin Orthop Relat Res.* 2005 Dec;441:115-24.
2. Jolles BM, Bogoch ER. (2006) Posterior versus lateral surgical approach for total hip arthroplasty in adults with osteoarthritis. *Cochrane Database Syst Rev.* ;3:CD003828
3. Masonis JL, Bourne RB.(2002) Surgical approach, abductor function, and total hip arthroplasty dislocation. *Clin Orthop Relat Res.*405:46-53. doi: 10.1097/00003086-200212000-00006.

4. Rachbauer F. (2006) Minimally invasive total hip arthroplasty via direct anterior approach. *Orthopade*35:723–730. doi: 10.1007/s00132-006-0964-4
5. Jewett BA, Collis DK.(2011) High complication rate with anterior total hip arthroplasties on a fracture table. *Clin Orthop Relat Res.* 469:503–507. doi: 10.1007/s11999-010-1568-1.
6. Phillip H. Horne and Steven A. Olson (2011) Direct anterior approach for total hip arthroplasty using the fracture table. *Curr Rev Musculoskelet Med.* 2011 Sep; 4(3): 139–145.
7. Barton C, Kim PR.(2009). Complications of the direct anterior approach for total hip arthroplasty. *Orthop Clin North Am*40(3):371–375. doi: 10.1016/j.ocl.2009.04.004.
8. Siguier T, Siguier M, Brumpt B.(2004). Mini-incision anterior approach does not increase dislocation rate: a study of 1037 total hip replacements. *Clin Orthop Relat Res.* 2004 Sep;(426):164-73.
9. Chimento GF, Pavone V, Sharrock N, Kahn B, Cahill J, Sculco TP.(2005) Minimally invasive total hip arthroplasty: a prospective randomized study. *J Arthroplasty.* 20:139–144.
10. Sculco TP, Boettner F.(2006). Minimally invasive total hip arthroplasty: the posterior approach. *Instr Course Lect.* 55:205–214.
11. Parker MJ, Maheshwer CB (1997) The use of a hip score in assessing the results of treatment of proximal femoral fractures. *Int Ortho* 21:262–264.
12. Ethgen O, et al.(2004) Health-related quality of life in total hip and total knee arthroplasty. A qualitative and systematic review of the literature. *J Bone Joint Surg Am.*86-A(5):963–974.
13. Jolles BM, Bogoch ER.(2006) Posterior versus lateral surgical approach for total hip arthroplasty in adults with osteoarthritis.
14. Masonis JL, Bourne RB.(2002) Surgical approach, abductor function, and total hip arthroplasty dislocation. *Clin Orthop Relat Res.*405:46–53.